

A Shy Girl?

Pauline and Guillaume
French Internist Team



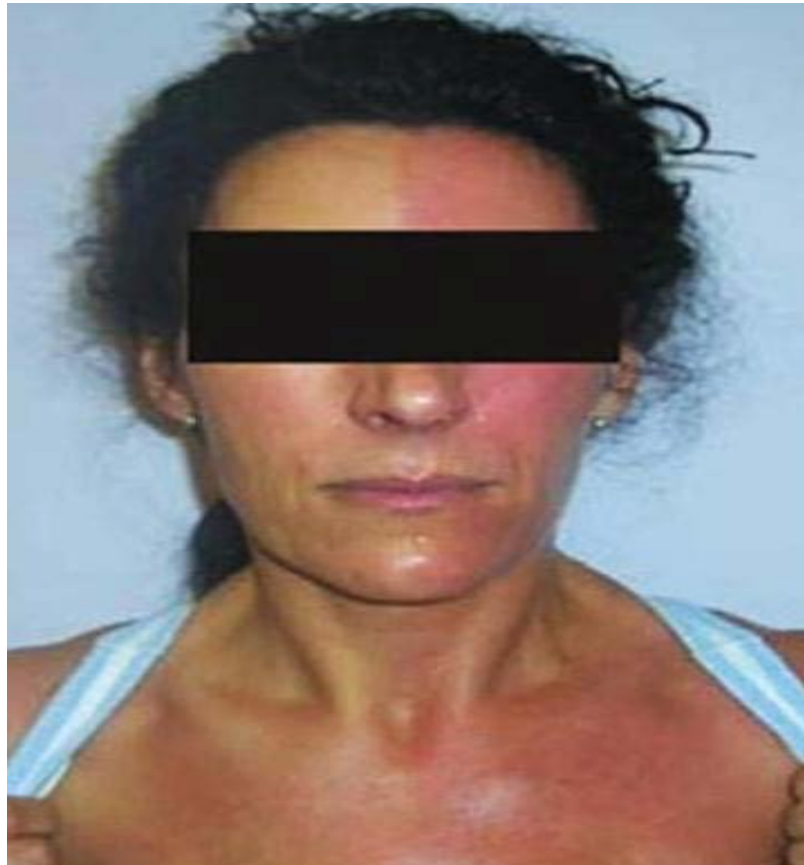Doctor, all my friends are laughing at me

- Anna, aged 24, no-smoking girl
- Taking oral contraceptive pills
- History of esophageal atresia well-operated at birth
- Nissen operation when she was 6
- Complaining of crisis of red hot sweating face since 2 years

Was it a flush???

- No pain no tear no fever
- Trigger factor : jogging
- Crisis of sweating erythema of the left side of the face
- Lasted for 20 minutes to an hour
- Neurological / Cardiological examination: normal
- Carotid doppler US / Cerebral MRI : normal

What is your diagnosis?



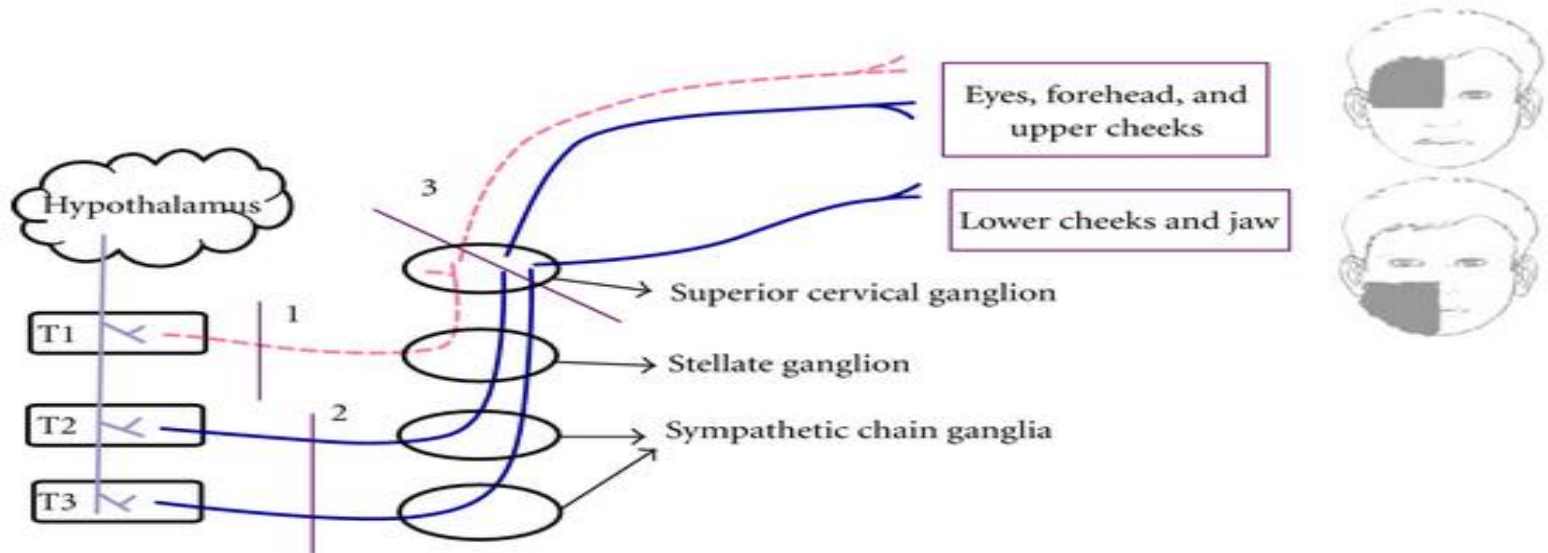


Harlequin syndrome (Lance et al. 1988)

Sweating and flush of one side of the face

- What could be the pathophysiology?
 - « abnormal » sympathetic nervous system response
 - trigger by exercise, warm, cold, emotion.

Which side of face is the pathologic one?



- (1) Ocular findings in Horner's syndrome are associated with lesions at the level of T1 or anywhere along its path
- (2) Sudomotor and vasomotor findings of Harlequin syndrome are secondary to the lesion at the levels, of T2 and T3 or anywhere along its path
- (3) Lesion at superior cervical ganglion will lead to combined features of both Horner's and Harlequin syndrome

--- Pupillomotor fibres
— Vasomotor and sudomotor fibres



The white!!!!

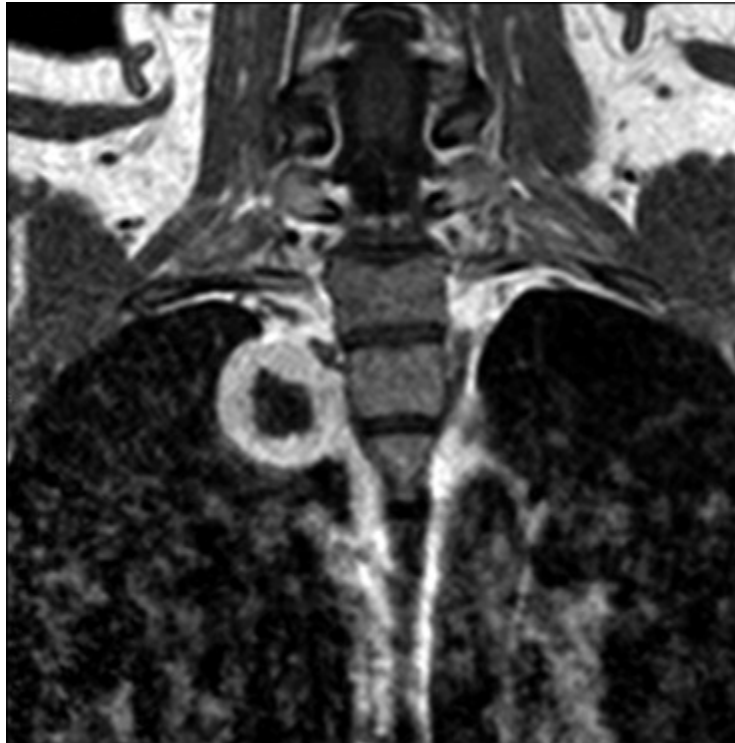
- The « normal » side of the face : interruption of the sympathetic nerves fibers, vasomotor deficit
- The red one : the vasodilatory response of the controlateral side often appears exaggerated, even if normal



An unusual complication

- Abnormalities of the first or second thoracic roots
 - Internal jugular catheterization
 - Surgical neck dissection
 - Complication of local anesthesia
 - Sympathectomy for hyperhidrosis

One interesting cause : Schwannoma of the T2-T3 level (Oller et al., Am J Med Apr. 2011)





For our patient...

- Cervical MRI normal
- No history of local anesthesia or carotid catheterization
- But there is an element which can help you for the underlying diagnosis...

Esophageal atresia and Harlequin Syndrome: sympathetic lesion during surgery

Journal of Pediatric Surgery (2009) 44, E27–E29



Journal of
Pediatric
Surgery

www.elsevier.com/locate/jped surg

Asymmetric sweating and flushing in infants with esophageal atresia[☆]

Denis A. Cozzi*, Ermelinda Mele, Giorgia Totonelli, Silvia Ceccanti,
Simone Frediani, Francesco Cozzi

Pediatric Surgery Unit, University of Rome "La Sapienza," 00161 Rome, Italy

Received 22 December 2008; revised 26 February 2009; accepted 10 March 2009



Key Points

- Red sweating unilateral face
- Sympathetic nervous system dysfunction
- Crisis, especially following physical exercise
- Be careful about a mass of the first or second thoracic root